

# SPECIFIC PATTERN OF <sup>18</sup>F-2-FLUORO-2-DEOXY-D-GLUCOSE POSITRON EMISSION TOMOGRAPHY IN DIFFERENTIAL DIAGNOSIS OF ALZHEIMER DISEASE: CASE REPORT

## AUTHORS

Radovic B.<sup>1,2</sup>, Brajkovic L.<sup>2</sup>, Nikolic S.<sup>1</sup>

<sup>1</sup> The Faculty of Medical Science University of Pristina, Kosovska Mitrovica

<sup>2</sup> Centre for Nuclear Medicine Clinical Centre of Serbia, Belgrade, Republic of Serbia

## CORRESPONDENT

Branislava Radović

The Faculty of Medical Science  
University of Pristina,  
Kosovska Mitrovica

tcmapple@gmail.com

## SUMMARY

**Introduction:** Dementia is a clinical diagnosis based on deficits of intellectual function, usually memory. Primarily neurodegenerative diseases are characterized by progressive neuronal damages and its synapsis. Early-onset Alzheimer disease occurs in someone younger than 65. <sup>18</sup>FDG-PET/CT is a quantitative tomographic technique also called a biomarker of neuronal activity.

**Case outline:** A female of 54, mother, 12 years of education, an accountant, was sent to FDG-PET/CT brain scan because of loss of memory, social withdrawal, apathy, behavior changes, troubles with paying bills, speaking difficulties with no structural imaging abnormalities. PET scan revealed glucose hypometabolism in parietal lobes, left posterior cingulum, parieto-temporal regions, the left parietooccipital region, left insula and temporal lobes.

A male of 43, father, army corporal, 12 years of education, was sent to metabolic hybrid imaging because suspected dementia. He expressed progressive behavior decline, in a year time. The patient wasn't cooperative, could not concentrate and confabulated a lot. Forgetfulness, decline in voluntary dynamics and apathy dominated the clinical presentation.

Structural imaging showed supratentorial, right precentral gyri solitary lesion and cortical bilateral hippocampal atrophy. FDG scan revealed distinctively diminished glucose metabolism posteriorly in parietal and temporal lobes, both posterior cingulum.

SPM analysis confirmed the visually observed pattern of hypometabolism in both patients.

**Conclusion:** Depression is an important consideration in the differential diagnosis of AD. Early detection of AD through molecular imaging techniques will assist the choice of medications to slow the progression of the disease and optimize patient care.

**Keywords:** Alzheimer, dementia, depression, FDG PET, brain, SPM

## SRPSKI

### SPECIFIČAN "OBRAZAC" POZITRONSKE EMISIONE TOMOGRAFIJE POMOĆU <sup>18</sup>F-2-FLUORODEOKSI-D-GLUKOZE U DIFERENCIJALNOJ DIJAGNOZI ALCHAJMEROVE BOLESTI: PRIKAZ SLUČAJA

Radović B.<sup>1,2</sup>, Brajković L.<sup>2</sup>, Nikolić S.<sup>1</sup>

<sup>1</sup> Univerzitet u Prištini-Kosovska Mitrovica, Medicinski fakultet, Kosovska Mitrovica, Republika Srbija

<sup>2</sup> Centar za nuklearnu medicinu Kliničkog centra Srbije, Beograd, Republika Srbija

#### SAŽETAK

**Uvod:** Demencija je klinička dijagnoza koju karakteriše deficit intelektualnih funkcija, najčešće memorije. Primarne neurodegenerativne bolesti su praćene progresivnim propadanjem neurona i njihovih sinapsi. Alzhajmerova demencija ranog početka se javlja kod osoba mlađih od 65 godina. <sup>18</sup>FDG-PET/CT je kvantitativna tomografska tehnika koja je i biomarker neuronske aktivnosti.

**Prikaz bolesnika:** žena od 54 godine, majka, 12 godina školovanja, računovođa, poslata je na PET sken mozga zbog gubitka memorije, povlačenja iz socijalnih aktivnosti, apatije, promena u ponašanju, teškoća u plaćanju računa, teškoćama u govoru. Na strukturnom imidžingu nije bilo promena. PET sken je otkrio hipometabolizam glukoze u parijetalnim režnjevima, levom zadnjem cingulumu, u parijetotemporalnim regionima levoj, insuli i u temporalnim režnjevima.

Muškarac od 43 godine, otac, 12 godina školovanja, desetar, poslat je na metabolički hibridni imidžing zbog sumnje na demenciju. U roku od godinu dana je pokazao pogoršanje u ponašanju: nije mogao da se koncentriše, zaboravljao je, voljni dinamizmi su značajno opali, konfabulirao je. Strukturni imidžing je ukazao na solitarnu leziju supratentorijalno u desnom

precentralnom girusu kao i obostranu atrofiju hipokampusa. FDG sken je otkrio značajno smanjen metabolizam glukoze posteriorno u parijetalnim i temporalnim režnjevima i u posteriornom cingulumu obostrano. SPM analiza je potvrdila vizuelno uočene obrasce hipometabilzma kod oba pacijenta.

**Zaključak:** U diferencijalnoj dijagnozi Alchajmerove demencije neophodno je razmotriti i depresiju. Rano otkrivanje AD pomoću tehnika molekularnog imidžinga omogućuje pravovremenu i odgovarajuću terapiju te usporiti tok bolesti i poboljšati lečenje obolelog.

**Ključne reči:** Alchajmer, demencija, depresija, FDG PET, mozak, SPM

## INTRODUCTION

We have presented two cases where FDG-PET/CT yielded accurate diagnosis of early onset Alzheimer dementia in contrast to major depressive disorder.

Depression is a mental illness defined in the Diagnostic and Statistical Manual of Mental Disorders (DSM). DSM-V criteria for diagnosis of depression (in this article, a term “depression” refers to major depressive disorder) requires five (or more) of the following symptoms during the same two week period and represent a change from previous functioning. At least one of the following symptoms is either depressed mood or loss of interest or pleasure: depressed mood most of the day (e.g., feels sad, empty, hopeless, appears tearful); markedly diminished interest or pleasure in all, or almost all, activities most of the day; significant weight loss when not dieting or weight gain, or decrease or increase in appetite nearly every day; insomnia or hypersomnia; psychomotor agitation or retardation (observable by others), feelings of restlessness or being slowed down; fatigue or loss of energy, feelings of worthlessness or excessive or inappropriate guilt; diminished ability to think or concentrate, or indecisiveness; recurrent thoughts of death, recurrent suicidal ideation or a suicide attempt or a specific plan for committing suicide. The symptoms cause clinically significant distress or impairment in social, occupational, or other important areas of functioning. Not all the patients exhibit every symptom every day and not with the same strength. According to the World Health Organization, depressive disorder (DD) is one of the most commonly diagnosed mental disorders among adults.<sup>[1,2]</sup>

Alzheimer disease (AD) is the most common dementia, which starts with impairment of memory followed by multiple domains of cognitive dysfunction. Other frequently encountered disorders include frontotemporal dementia (FTD) and dementia with Lewy bodies (DLB). AD accounts for 50%-60% of dementias, with FTD and DLB each accounting for approximately 15%-25%. When Alzheimer's disease occurs in someone under the age of 65, it is known as early-onset AD.<sup>[3,4]</sup>

There are two systems currently used in diagnoses of AD: the International Working Group (IWG) for New Research Criteria for the Diagnosis of Alzheimer's Disease and the National Institute on Aging-Alzheimer's Association (NIA-AA) criteria. IWG, in 2007, proposed to anchor the diagnosis of AD on the presence of biomarkers. NIA-AA criteria, has expanded coverage of the full range of disease stages, from the asymptomatic through the most severe stages of dementia. Two core diagnostic criteria that were proposed by IWG are: clinical, specific episodic memory profile characterized by a low free recall (which differs from that observed in non-AD disorders such as frontotemporal dementias, progressive supranuclear palsy, Huntington's disease, **major depression**, or even normal aging), and the presence of **biomarkers**

consistent with and supportive of AD on structural MRI: molecular neuroimaging with PET (18F-2-fluoro-2-deoxy-D-glucose PET [FDG PET] or 11 C-labelled Pittsburgh compound B PET [PiB PET]); or CSF analysis of amyloid  $\beta$  ( $A\beta$ ) or tau protein (total tau [T-tau] and phosphorylated tau [P-tau]) concentrations.

The NIA-AA diagnostic criteria, published in 2011, cover the full staging of the disease: asymptomatic (preclinical AD), predementia (MCI (mild cognitive impairment)) due to AD, and dementia (due to AD). Both IWG and NIA-AA diagnostic criteria include biomarkers in the diagnostic process and the recognition of an asymptomatic biomarker-positive stage. “Topographical” biomarkers identify downstream brain changes indicative of the regional distribution of Alzheimer's pathologies, such as temporal lobe atrophy on MRI or *reduced glucose metabolism in temporoparietal regions on FDG-PET*. “Pathophysiological” biomarkers are direct in vivo indicators of brain amyloidosis and tauopathy, including amyloid tracer PET scans and CSF concentrations of  $A\beta$ 2, T-tau, and P-tau. Therefore, post mortem histopathologic finding of amyloid plaque and neurofibrillary tangles in the brain is the standard of reference for the diagnosis of AD.<sup>[5,6]</sup>

It has been shown that among topographical markers FDG-PET has good sensitivity in the detection of early brain dysfunction in AD and that it follows disease evolution over time. FDG brain uptake is a sensitive marker of synaptic dysfunction, so the topography of brain hypometabolism accurately maps on clinical symptoms. Patients with AD with predominant memory and cognitive impairment show the classic pattern of reduced FDG brain uptake in temporoparietal association areas including the precuneus and posterior cingulate cortex, whereas in patients with AD with focal neuropsychological deficits (language, praxis, or visuospatial dysfunction) hypometabolism affects the pertinent neocortical area. Glucose metabolic reduction in medial temporal lobe including the hippocampus is also present even in the early stage of AD, but is not always clearly shown in FDG-PET image, despite obvious hippocampal atrophy, observed on structural imaging. In the moderate-to-severe stages of AD, hypometabolic regions spread to the frontal association cortices, while metabolism in the striatum, thalamus, primary sensorimotor cortices, visual cortices, and cerebellum are relatively preserved despite disease progression.<sup>[7]</sup>

Positron emission tomography (PET) is a tomographic technique that computes the three-dimensional distribution of radioactivity based on the annihilation photons that are emitted by positron emitter labeled radiotracers. <sup>18</sup>F-DG is suitable for imaging regional cerebral glucose consumption with PET since it accumulates in neuronal tissue by facilitated transport of glucose and hexokinase mediated phosphorylation. It is therefore referred as biomarker of neuronal activity. An integrated PET/CT system is a combination of a PET and a CT scanner with a single patient table (<sup>18</sup>F-fluorodeoxyglucose-positron emission tomography/computed tomography, FDG-PET/CT).<sup>[8-14]</sup>

Statistical Parametrical Mapping (SPM) of FDG-PET images has been used in the quantitative evaluation of brain metabolic changes in neurodegenerative conditions. It shows specific topographic patterns associated with cognitive decline and dementia. Each individual FDG-PET scan is first warped in the standard MNI (Montreal Neurological Institute) referent space using a template image for spatial normalization and subsequently smoothed with a 3D Gaussian kernel filter. Parametric analysis of FDG-uptake in SPM is obtained using voxel level statistical parametric mapping at the whole-brain level, in the framework of the general linear model by means of a two-sample t-test, comparing each subject image against images pertaining to a reference control group. The comparison between each individual and the reference group yields a contrast t-map testing for areas with relative decreases in metabolism (i.e. hypometabolism) compared to the controls. Map of Significance values from the voxel-wise t-test ( $p < 0,05$ ) are finally reported.<sup>[15,16,17]</sup>

It is sometimes very difficult to differentiate depression from early-onset dementia due to overlapping clinical symptoms and neuropsychological findings. Since the appropriate treatment depends on accurate diagnosis, it is important to accurately distinguish between these disorders.

### CASE OUTLINE ONE

A female 54 years old, married, mother of two, 12 years of education, employed as an accountant, was sent to Centre for Nuclear Medicine Clinical Centre of Serbia. Loss of memory, forgetfulness, mood swings, social withdrawal, apathy, behaviour changes, loss of working efficiency, troubles with paying bills and handling money, difficulties in everyday activities, speaking difficulties (nominations), dominated the clinical presentation. She was disoriented to space, Mini Mental Score Examination (MMSE) deteriorated in two years from 21/30 to 17/30 (orientation to time 4, orientation to space 4, memory 3, attention and calculation 0, recall 0, registration 0, nomination 2, following simple instruction 1, drawing figure 0, writing the word 1, complex commands 2). Test battery for diagnosing dementia showed as follows: ADAS ADL (Alzheimer Disease assessment Scale; The activity of Daily Living) 58/78; RAVLT (Rey Auditory Verbal Learning Test) A1:3, A2:2, A3:3, A4: 3, A5:2, B1: 0, A6:0; false recognition 12, recognition 13); Bender Gestalt test learning score 2; fluency (S:9, K:4, L:3, overall phonetic fluency 16); Boston naming test 57; Mattis 102 (attention 32, initiation/preservation 23, construction 5, conceptualisation 30, memory 12); Addenbrook test 58 (attention 11, memory 3, fluency 6, language 19, visual and spatial abilities 9). Neuropsychological examination revealed cognitive decline in the patient. Structural imaging (CT and MRI) showed no abnormalities. The neurological examination findings (with the exception of disorientation to space) were insignificant. The patient was treated with antidepressants and synthetic thyroxin. Family history showed no dementia. Therefore initial diagnoses were early-onset Alzheimer disease, logopenic form of frontotemporal dementia, depression and hypothyroidism as possible causes of cognitive impairment. Establishing the right diagnosis was important due to proper treatment and work ability assessment.

A standard hybrid imaging (FDG-PET/CT) static brain study was performed. After fasting of at least 4 h and after confirming normal blood glucose level just before the study, the patient was injected with 130 MBq (3.5 mCi) of <sup>18</sup>F-FDG

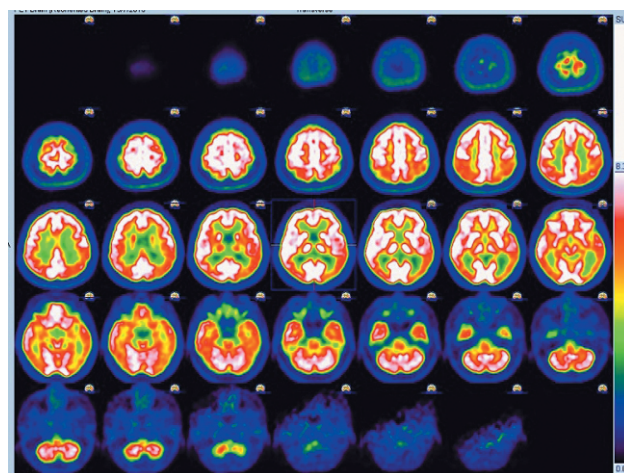
intravenously, while resting supine with eyes closed in a silent, dimly lit room. Antidepressants were not withheld prior to the PET study. Images were acquired 45 min after FDG injection (3-D mode, 1 bed, 15 min) by PET/CT (Biograph 64, True Point, SIEMENS) with trans axial resolution of 5.9 mm (full width at half maximum). Images were displayed as a series of 35 transaxial slices with a standard colour scale according to maximum standardized uptake value (SUV max) after reconstruction using an iterative method (OSEM) and attenuation and scatter corrections. Images were displayed for analysis on a Syngo Multimodality Workplace (Siemens AG). The image was analysed visually and by SPM analysis. Qualitative visual assessment of all images was performed by an experienced reader, who specialized in both nuclear medicine and neurology.

Imaging protocol was as follows: a) low-dose CT (40 mA) without contrast media b) FDG-PET scan. Quantitative voxel-based statistical image analysis was performed using SPM methodology. To obtain hypometabolic maps for the patient, single-subject SPM analysis was performed by a voxel-based statistical comparison between patient's functional images and functional images of cognitively intact controls from a database provided by the INLAB SPM web service.

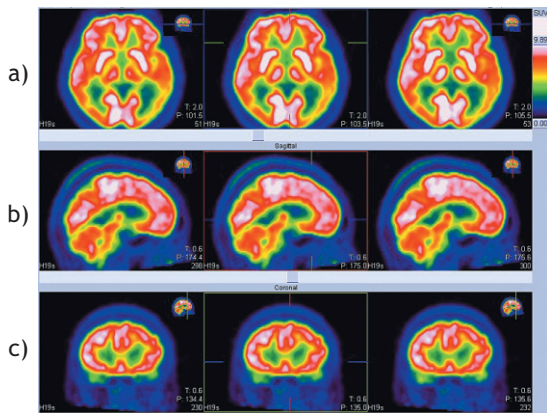
FDG-PET/CT scan revealed diminished cortical and subcortical glucose metabolism posteriorly in both hemispheres, dominantly on the left side. Glucose brain metabolism was preserved in striatum, thalamus and cerebellum. (Figure 1.) Regional hypometabolism was shown as follows: in parietal lobes, lateral and medial, more pronounced on the left, left insula, both parietotemporal regions (more on the left), left parietooccipital region, both temporal (polar, mesial, lateral) more on the left (Figure 2.), in posterior left cingulum (Figure 3.).

SPM analysis confirmed findings on visually estimated FDG-PET scans (Figure 4.).

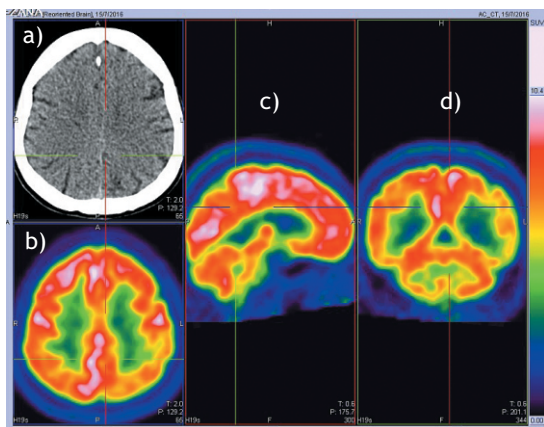
*Figure 1. Transversal FDG-PET image: pattern of regional glucose hypometabolism in the patient: both side parietotemporal hypometabolism (more on the left: thick arrows); preserved metabolism in striatum and thalamus.*



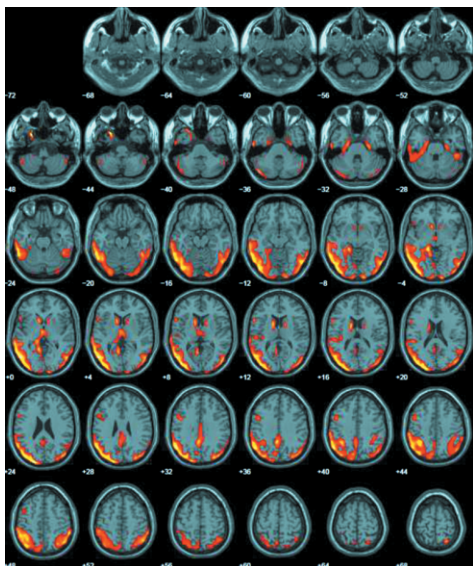
**Figure 2.** a) transversal FDG-PET image: parietotemporal on both sides (more on the left side: thick arrows),  
 b) sagittal FDG-PET image: left posterior cingulum (thick arrow) and left precuneus hypometabolism;  
 c) left side slight frontal hypometabolism.



**Figure 3.** a) low-dose CT scan showing no structural abnormalities;  
 (b), (c), (d) transversal, sagittal and frontal FDG brain image;  
 b) both sides parietotemporal (more on the left (dotted arrow), posterior cingulum (thick arrow));  
 c) left posterior cingulum (thick arrow);  
 d) parietal lateral and medial hypometabolism on the left parietal lobe and lateral hypometabolism on the right parietal lobe



**Figure 4.** The SPM t-maps of regional glucose hypometabolism: bilateral temporoparietal hypometabolism more on the left (arrowhead), both parietotemporal and posterior cingulum (dashed arrow): characteristic pattern for AD



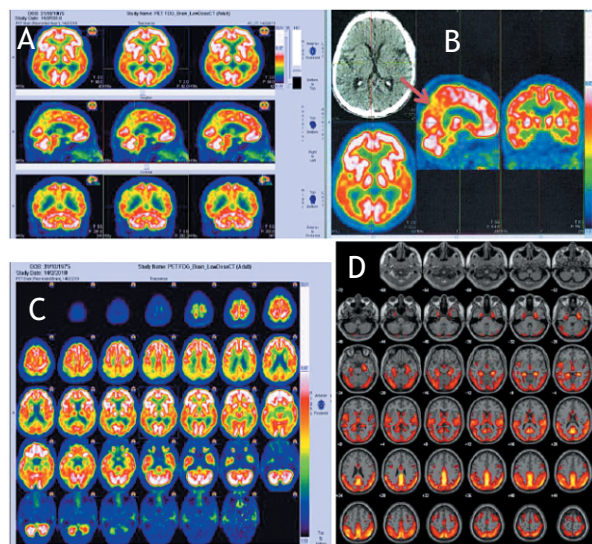
## CASE OUTLINE TWO

A male, 43 years old, married, army corporal, 12 years of education was sent to metabolic hybrid imaging (FDG-PET/CT) because the diagnosis of dementia could not be established with certainty. He expressed progressive behaviour decline, fears, over-sweating, in a year time and occasionally stammering. There was no lateralisation neurologically. MMSE was 13/30 (orientation to space 0; orientation to time 0; memory 3; attention and calculation 0; recall 0; nomination 2; registration 1; following simple instruction 3; verbal instruction 1; writing the word 1; drawing 0). RAVLT A1: 2; A2: 2; A3: 2; A4: 2; A5: 2; A6: 0 B1: 0; recognition 0; false recognition 0). The patient was not cooperative, shivered a lot, could not concentrate and confabulated a lot. Forgetfulness, difficulties in a car driving, a decline in voluntary dynamics and apathy dominated the clinical presentation. His father was diagnosed as early-onset dementia, thirty years ago.

Structural imaging (CT and MRI) showed T2 hyper dense supratentorial, right precentral gyri solitary lesion most probably of the vascular origin. Cortical bilateral hippocampal atrophy was observed as well. ELISA positive anti-toxoplasma antibodies did not require antibiotic therapy. Thyroid function was preserved. ELISA antibodies to HIV, HCV and Borelli were negative. Cerebrospinal fluid had no abnormalities. Antidepressants were prescribed.

FDG-PET scan revealed distinctively diminished glucose metabolism posteriorly in both hemispheres. Medial and lateral parietal hypometabolism was shown both sides as well as both sides posterior cingulum, both temporal and insular (more on the left side). Glucose brain metabolism was preserved in striatum, thalamus and cerebellum (Figure 5.). SPM analysis confirmed visually estimated functional images.

**Figure 5.** A (first row) and C. Transversal FDG-PET image: both side temporal and insular hypometabolism (more on the left);  
 A (second row) and B. sagittal FDG-PET image: hypometabolic posterior cingulum on both sides (red arrow);  
 A. (third row) coronal FDG-PET images: medial and lateral parietal hypometabolism on both sides;  
 B. CT image with FDG-PET slices;  
 D. The SPM t-maps of regional glucose hypometabolism confirm that both side parietotemporal and posterior cingulum hypometabolism is statistically significant



## CONCLUSION

These two cases, amongst many similar cases, studied in the Centre for Nuclear Medicine Clinical Centre of Serbia on everyday basis, confirmed high diagnostic accuracy of specific hypometabolism pattern in AD.

Both patients were finally diagnosed with early onset Alzheimer disease, after four years and one year, respectively, of diagnostic procedures. They have expressed rapid cognitive decline and showed no response to antidepressive therapy. Therefore, both were sent to FDG-PET to be

evaluated for neurodegenerative dementia, since early onset AD is more progressive than the senile one. AD is clinically presented in an atypical way, making the diagnostic confusion.

FDG-PET showed in both cases, regional hypometabolism pattern typical for Alzheimer dementia: severely diminished glucose metabolism in bilateral parietotemporal regions and in posterior cingulum.

Establishing the diagnose of early-onset AD led to change in overall therapy as well as working ability evaluation, in both patients.

## REFERENCES

1. [https://images.pearsonclinical.com/images/assets/basc-3/basc3resources/DSM5\\_DiagnosticCriteria\\_MajorDepressiveDisorder.pdf](https://images.pearsonclinical.com/images/assets/basc-3/basc3resources/DSM5_DiagnosticCriteria_MajorDepressiveDisorder.pdf)
2. <http://apps.who.int/iris/bitstream/10665/254610/1/WHO-MSD-MER-2017.2-eng.pdf>
3. Mosconi L, Tsui WH, Herholz K, et al. Multicentre standardized 18F-FDG PET diagnosis of mild cognitive impairment, Alzheimer's disease, and other dementias: Official Publication, Society of Nuclear Medicine Journal of Nuclear Medicine 2008; 49 (3): 390-398
4. Panegyres PK, Rogers JM, McCarthy M, Campbell A and Wu JS Fluorodeoxyglucose-Positron Emission Tomography in the differential diagnosis of early-onset dementia: a prospective, community-based study. BMC Neurology 2009; 12:9-41
5. Ishii K. PET Approaches for Diagnosis of Dementia. Am J Neuroradiol 2014; 35: 2030 -38
6. Perani D, Cerami C, Caminiti SP, Santangelo R, Coppi E, Ferrari L, Pinto P, Passerini G, Falini A, Iannaccone S, Cappa SF, Comi G, Gianolli L, Magnani G. Cross-validation of biomarkers for the early differential diagnosis and prognosis of dementia in a clinical setting Eur J Nucl Med Mol Imaging 2016; 43: 499-508
7. Herholz K: FDG PET and differential diagnosis of dementia. Alzheimer Dis Assoc Disord 1995; 9:9-16
8. Ishii K. PET Approaches for Diagnosis of Dementia. Am J Neuroradiol 2014; 35: 2030 -38
9. Boellaard R, Delgado-Bolton R, Oyen WJG, Giammarile F, Tatsch K, Eschner W, et al. FDG PET/CT: EANM procedure guidelines for tumour imaging: version 2.0. Eur J Nucl Med Mol Imaging 2015; 42:328-354.
10. Varrone A, Asenbaum S, Borghat TV, Booi J, Nobili F, Någren K, Darcourt J, Kapucu OL, Tatsch K, Bartenstein P, VanLaere K. EANM procedure guidelines for PET brain imaging using [18F]FDG, version 2. Eur J Nucl Med Mol Imaging 2009; 36 (12): 2103-10
11. Asenbaum S. Guideline for the use of FDG PET in Neurology and Psychiatry. Austrian Society of Nuclear Medicine 2001. [http:// www.ogn.at](http://www.ogn.at).
12. Kuwert T, Bartenstein P, Grünwald F, et al. Clinical value of positron emission tomography in neuromedicine. Position paper on results of an interdisciplinary consensus conference. Nervenarzt 1989; 69:1045-160.
13. Mazziotta JC, Frackowiak RSJ, Phelps ME: The use of positron emission tomography in the clinical assessment of dementia. Sem Nucl Med 1992; 22: 233-246.
14. Coleman RE, Positron Emission Tomography Diagnosis of Alzheimer's Disease. PET Clin 2007; 2: 25-34.
15. Anchisi D, Borroni B, Franceschi M, et al. Heterogeneity of brain glucose metabolism in mild cognitive impairment and clinical progression to Alzheimer disease. Archives of Neurology 2005; 62 (11): 1728-1733
16. Perani D, Della Rosa PA, Cerami C, Gallivanone F, Fallanca F, Vanoli EG, Panzacchi A, Nobili F, Pappatà S, Marcone A, Garibotto V, Castiglioni I, Magnani I, Cappa SF, Gianolli L, EADC-PET Consortium. Validation of an optimized SPM procedure for FDG-PET in dementia diagnosis in a clinical setting. Neuroimage Clin 2014; 6: 445-454.
17. Yakushev I, Hammers A, Fellgiebel A, et al., 2009. SPM-based count normalization provides excellent discrimination of mild Alzheimer's disease and amnesic mild cognitive impairment from healthy aging. Neuroimage 2009; 44 (1): 43-50.