

THE ECTOPIC SPLEEN-INCIDENTAL FINDING ON PELVIC MAGNETIC RESONANCE IMAGING

AUTHORS

Bünyamin Güney¹, Emrah Doğan¹, Murat Yunus Özdemir¹, Rabia Mihriban Kılıncı¹
¹ Muğla Sıtkı Koçman University, Faculty of Medicine, Radiology

CORRESPONDENT

Ass. Pr. Bunyamin Güney
 Muğla Sıtkı Koçman University
 Education and Research Hospital
 Turkey
 dr_e_dogan@hotmail.com

SUMMARY

The ectopic spleen (ES) is a rare variation occurred depend on the absence or laxity of the suspensory ligaments. The ES is a rarely diagnosed clinical condition. Less than 500 symptomatic patients have been reported. Less than 0.25% of splenectomies are performed on the ES. Patients are usually asymptomatic. It's diagnosed incidentally in general. The incidence is not clear. ES incidence is reported less than 0.5%. However, this rate covers all of the relocations. The spleen can be found anywhere in the abdomen or pelvis, depends on the length of the vascular pedicle. The pelvic ES is a rarely encountered situation. Knowing this anomaly is essential for early diagnosis and prevention serious problems such as torsion, infarction and acute abdomen. A 21 years old female patient with ES was presented on pelvic magnetic resonance imaging.

Keywords: ectopic spleen, magnetic resonance imaging, splenic torsion

INTRODUCTION

Spleen variations are common encountered in daily routine. Variations include common ones such as the accessory spleen but also rare types such as the ectopic spleen (ES). Less than 500 symptomatic cases of ES have been reported, and less than 0.25% of splenectomies are performed caused by ES. Patients are usually asymptomatic. ES incidence is less than 0.5%. However, this rate covers all of the relocations (1). The pelvic ES is a rarely encountered condition. Since the spleen is a reticuloendothelial system organ, the variations like accessory spleen can be misdiagnosed as lymph nodes because of similarity with sonographic echogenicity and computed tomography density. The ectopic spleen may be confused with mass and may be damaged during procedures such as blind paracentesis. Advanced imaging techniques such as magnetic resonance imaging (MRI) are not routinely diagnosis of the ectopic spleen because these lesions are usually asymptomatic. For this reason, clinical physicians and radiologists rarely encounter with MRI appearance of the ectopic spleen. The incidence of trauma, torsion, and infarction increase in the presence of ES. Knowing the presence of ES increases the accuracy of diagnosis in patients with trauma (1,2). A 21 years old female patient with incidentally detected pelvic ES was presented accompanying by MRI findings.

CASE REPORT

A 21-year-old female patient was admitted to the dermatology clinic for erythematous skin rashes. In

radiological assessment, hepatobiliary ultrasonography was showed fatty liver and parenchymal nonspecific hypoechoic areas near the portal hilum. The gallbladder and bile ducts were normal.

In the laboratory, liver function tests and blood haemogram values were normal. Upper abdominal MRI was requested because of detected hypoechoic liver areas on ultrasound. On MRI, there was diffuse hepatic steatosis except for the parenchyma around the portal vein. The hypoechoic sonographic focuses in the liver were evaluated to be focal fatty sparing of the liver. However, the spleen was not observed in normal localization in the left upper quadrant. An appearance similar to a mass was detected in the left lower quadrant of the abdomen in the lower sections of MRI imaging, so the radiological examination was shifted to the pelvic region. Pelvic MRI showed an ES located in the left iliac fossa. Hilum was in 180 degrees rotation according to normal. Thereby, rotation anomaly was present (Figure 1A and 1B).

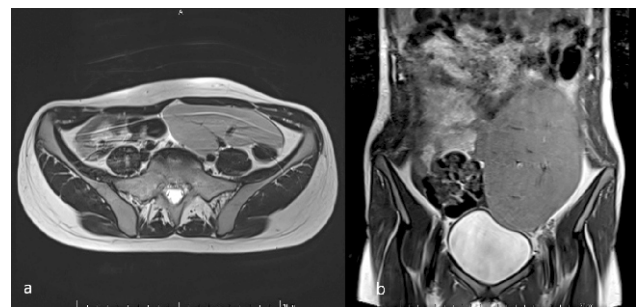


Figure 1A and 1B. Axial (1A) and coronal (1B) T2-weighted images; localized in the left iliac fossa, the hilum was 180 degrees rotation opposite to normal (posterolateral ectopic spleen)

Spleen size was in the upper limit of normal (125x42 mm). On T1 and T2 weighted images, parenchymal signals were similar to normal spleen signal. On contrast-enhanced images, the parenchyma homogeneously enhanced. There were no contrast defects typical of infarction (Figures 2A and 2B) or an accessory spleen.

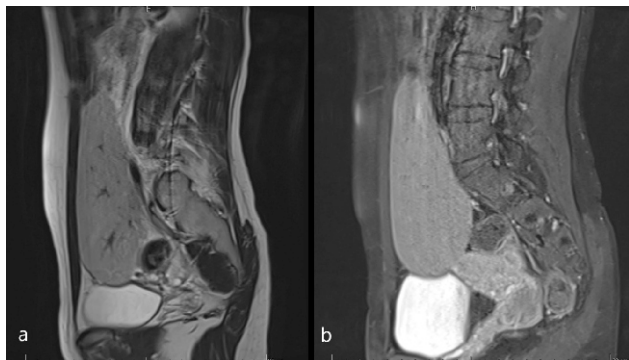


Figure 2A and 2B. In sagittal T2 (2A) and post-contrast T1 (2B) weighted images. parenchymal enhancement in the ectopic spleen is homogeneous

DISCUSSION

The spleen is an organ located in the left hypochondrium, surrounded by the stomach, diaphragm, and left colonic flexure. When the spleen is located outside of its normal location, it is described as an ectopic spleen (ES). It is also referred to as the mobile spleen (wandering spleen). Gastrosplenic, splenocolic and splenorenal ligaments are the anatomic structures that hold the spleen in the left subdiaphragmatic region. Because of the laxity or absence normal ligaments that attach the spleen to the left upper quadrant, it relocates. The spleen can be found anywhere in the abdomen depends on the length of vascular pedicle (1,2,3). In our case it was pelvic localization. It is frequently seen in women aged 20-40 years. It is 7 times more common in females (4). Our case was a 21-year-old female.

Although the etiology of ES is not known clearly, it is thought to be the result from the lack of fusion seen in the development of dorsal mesogastrium triggered with long pedicles (5). Prune-Belly syndrome may cause ES in the insufficiency of anterior bowel rotation (6). In adults, acquired ES may be seen due to trauma, previous abdominal surgery and muscular atrophy. In women, it is thought that the increased estrogen hormone during pregnancy contributes to the relaxation of the spleen's suspensory ligaments.

Even if ES cases are mostly asymptomatic, they can cause non-specific complaints such as abdominal pain, nausea, and vomiting due to the compression effect on abdominal organs. The most serious and feared complication is torsion. Patients with torsion develop severe abdominal pain, fever, nausea, and vomiting. Physical examination shows a palpable mass in the abdomen (7). Laboratory tests are generally non-specific, but signs of increased inflammatory parameters, hypersplenism, and functional asplenia may occur. Our case had no active complaint.

The diagnosis of ES is usually made incidentally by imaging methods taken for a different reason. Spleen shadow is not observed in normal localization on abdominal X-ray. The localization, size and blood supply of the spleen can be evaluated by ultrasonography. If torsion has developed, there is no blood supply in the splenic hilum and parenchyma, increased arterial resistance, and decreased venous flow (8). The spleen is not in normal localization on computed tomography. A similar density with the spleen, the existence of the hilum and morphologic appearance are diagnostic. The spiral appearance of splenic vessels and significant decrease in spleen density compared to the liver are evidence of torsion.

The contrast-enhanced computed tomography also provides information about the blood supply of the spleen. The absence of parenchymal contrast enhancement is auxiliary to the diagnosis of torsion (9). In our case, parenchymal enhancement was homogeneous. There was no contrast defect in favor of infarct. Also, accessory spleen tissue was not observed in another localization on abdominal MR images.

The treatment of asymptomatic patients is conservative. Splenopexy operations have become prominent in cases without signs of infarct, torsion and hypersplenism because of the importance of the spleen in the immune system and the increase in fatal infections after splenectomy. In the case of torsion, detorsion is tried and the viability of the spleen is evaluated. Despite detorsion, if the viability of the spleen does not return, splenectomy is inevitable, and infarction occurs (8). In recent years, laparoscopic splenectomy is the most preferred surgical method because of the short hospitalization time and faster recovery period.

CONCLUSION

In conclusion, the ES is a rare clinical entity diagnosed incidentally in general. It should be kept in mind in patients as one of the causes of acute abdomen. The diagnosis of the ES and its complications can be detected by radiological imaging.

REFERENCES

1. Qazi SA, Mirza SM, Muhammad AM, Al Arrawi MH, Al-Suhaibani YA. Wandering spleen. Saudi J Gastroenterol. 2004 Jan;10(1):1-7. PMID: 19861821. URL: <https://pubmed.ncbi.nlm.nih.gov/19861821/>
2. Blouhos K, Boulas KA, Salpigktidis I, Baretas N, Hatzigeorgiadis A. Ectopic spleen: An easily identifiable but commonly undiagnosed entity until manifestation of complications. Int J Surg Case Rep. 2014;5(8):451-4. doi: 10.1016/j.ijscr.2014.05.010. Epub 2014 May 28. PMID: 24973525; PMCID: PMC4147574. URL: <https://pubmed.ncbi.nlm.nih.gov/24973525/>
3. Gayer G, Zissin R, Apter S, Atar E, Portnoy O, Itzhak Y. CT findings in congenital anomalies of the spleen. Br J Radiol. 2001 Aug;74(884):767-72. doi: 10.1259/bjr.74.884.740767. PMID: 11511506. URL: <https://pubmed.ncbi.nlm.nih.gov/11511506/>

4. Feroci F, Miranda E, Moraldi L, Moretti R. The torsion of a wandering pelvic spleen: A case report. *Cases J.* 2008;1(1):149. Published 2008 Sep 10. doi:10.1186/1757-1626-1-149 URL: <https://www.ncbi.nlm.nih.gov/pmc/articles/PMC2553057/>
5. Varga I, Galfiova P, Adamkov M, Danisovic L, Polak S, Kubikova E, Galbavy S. Congenital anomalies of the spleen from an embryological point of view. *Med Sci Monit.* 2009 Dec;15(12):RA269-76. PMID: 19946246. URL: <https://pubmed.ncbi.nlm.nih.gov/19946246/>
6. Lebron R, Self M, Mangram A, Dunn E. Wandering spleen presenting as recurrent pancreatitis. *JSLs.* 2008;12(3):310-313. URL: <https://www.ncbi.nlm.nih.gov/pmc/articles/PMC3015861/>
7. Danaci M, Belet U, Yalin T, Polat V, Nurol S, Selçuk MB. Power Doppler sonographic diagnosis of torsion in a wandering spleen. *J Clin Ultrasound.* 2000 Jun;28(5):246-8. doi: 10.1002/(sici)1097-0096(200006)28:5<246::aid-jcu6>3.0.co;2-#. PMID: 10800003. URL: <https://pubmed.ncbi.nlm.nih.gov/10800003/>
8. Soleimani M, Mehrabi A, Kashfi A, Fonouni H, Büchler MW, Kraus TW. Surgical treatment of patients with wandering spleen: report of six cases with a review of the literature. *Surg Today.* 2007;37(3):261-9. doi: 10.1007/s00595-006-3389-0. Epub 2007 Mar 9. PMID: 17342372. URL: <https://pubmed.ncbi.nlm.nih.gov/17342372/>
9. Ben Ely A, Zissin R, Copel L, Vasserman M, Hertz M, Gottlieb P, Gayer G. The wandering spleen: CT findings and possible pitfalls in diagnosis. *Clin Radiol.* 2006 Nov;61(11):954-8. doi: 10.1016/j.crad.2006.06.007. PMID: 17018308. <https://pubmed.ncbi.nlm.nih.gov/17018308/>